


PRESENTING CLINICAL SIGNS

DATE History: Recheck degenerative valve disease. Asymptomatic. Receiving pimobendan 2.5 mg BID.

ECHOCARDIOGRAPHIC FINDINGS

7/27/22 2D, M-mode, and Doppler study. This exam is compared to the one performed 6/28/21.

PERFORMED BY:

Dr. Meredith Swart

There is mild left atrial dilation. The mitral valve leaflets are thickened and exhibit systolic prolapse. A mild to moderate jet of eccentric mitral regurgitation is present. There is borderline mild left ventricular dilation. Left ventricular systolic function is normal. The aorta and aortic valve are normal. Right atrial and right ventricular dimensions are normal. The tricuspid valve appears normal, though trivial tricuspid regurgitation is present. The pulmonary artery and pulmonic valve are normal. No pericardial effusion or cardiac masses are seen.

INTERPRETED BY

 Keith Blass, DVM,
 MS, DACVIM
 (Cardiology)

LA - 32.3 mm (prev. 33.1 mm)
 LVIDd - 29.0 mm (prev. 31.0 mm)
 LVIDs - 18.1 mm (prev. 18.8 mm)
 FS - 37.6% (prev. 39%)
 LVOT - 1.76 m/s (prev. 1.38 m/s)
 RVOT - 1.23 m/s (prev. 1.34 m/s)

PATIENT

Mollie Darmanin

ASSESSMENT/RECOMMENDATIONS

Degenerative mitral valve disease

SPECIES

Canine

This examination demonstrates no progression of Mollie's mitral valve disease over the past 13 months. As such, Mollie's mitral valve disease still appears to be well-compensated, and her current risk for the development of clinical signs secondary to it, such as coughing, exercise intolerance, syncope, and labored breathing, still appears to be relatively low.

BREED

Cocker Spaniel

No change in therapy is recommended at this time.

A recheck echocardiogram is recommended in 9 months. Thoracic radiographs are recommended if Mollie experiences respiratory clinical signs.

SEX

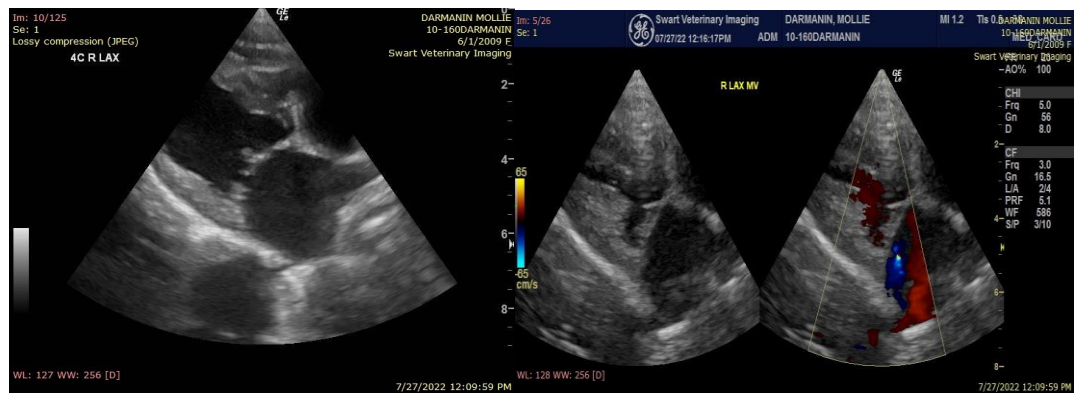
FS

AGE

13 y

WEIGHT

17 lb


HOSPITAL NAME

 Swart Veterinary
 Imaging

REFERRING VET

Dr. Swart



DATE

7/27/22

The information and recommendations provided are based on the images presented by the referring veterinarian. No evaluation can be communicated regarding pathology that was not visible in the image/video clips provided.

Thank you for this referral. If the clinical or image interpretation does not parallel your findings or if I can be of any further assistance please contact me.

PERFORMED BY:

Dr. Meredith Swart

Keith Blass, DVM, MS, DACVIM (Cardiology)
KeithBlass@gmail.com
631-804-5754

INTERPRETED BY

Keith Blass, DVM,
MS, DACVIM
(Cardiology)

PATIENT

Mollie Darmanin

SPECIES

Canine

BREED

Cocker Spaniel

SEX

FS

AGE

13 y

WEIGHT

17 lb

HOSPITAL NAME

Swart Veterinary
Imaging

REFERRING VET

Dr. Swart